

Figure 2 Iris hypoplasia, cataract, corectopia, and posterior embryotoxon (A), and shallow anterior chamber with corneal opacity (B) were among the anterior segment manifestations of the anomaly

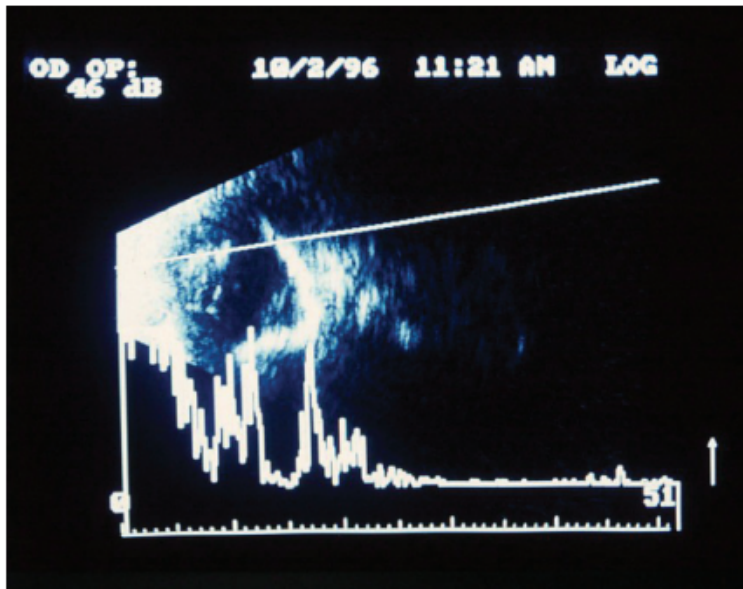


Figure 3 Ultrasonography showing the presence of dense retroretinal echogenicities and retinal elevation