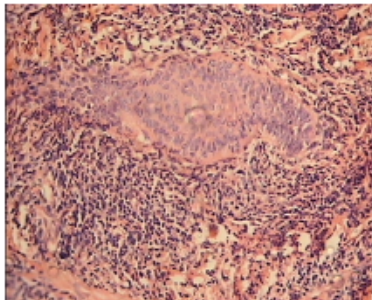


A



B

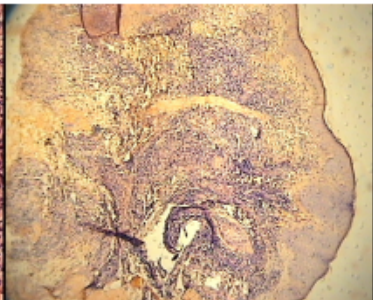


Figure 2 Moderately dense lymphocytic infiltration is present around the dermis and pilosebaceous follicles (haematoxylin and eosin staining) at (A) low power and (B) high power
