

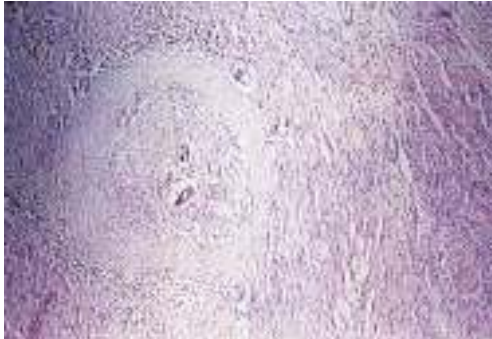Figure 1 An epithelioid granuloma within the leiomyoma

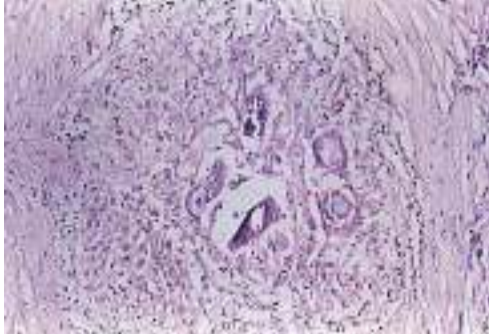


Figure 2 An epithelioid granuloma with multiple calcified bilharzial ova

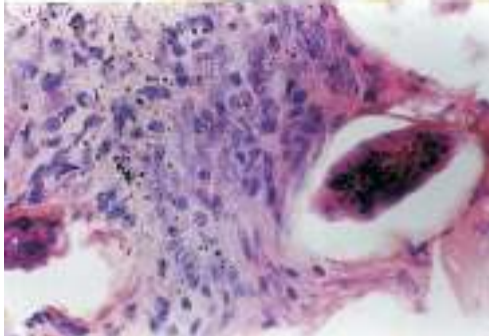


Figure 3 Two calcified bilharzial ova within the leiomyoma
